

THE ANAESTHETIC MANAGEMENT OF A COMPROMISED AIRWAY SECONDARY TO LEMIERRE'S SYNDROME

D. Levy¹, K. Flower¹, T. Hinde¹, T. Ali¹, C. Vinall², A. Varvinskiy¹

¹*Department of Anaesthesia and Perioperative Medicine, Torbay Hospital, Torquay, United Kingdom*

²*Department of Oral and Maxillofacial surgery, Royal Devon and Exeter Hospital, Exeter, United Kingdom*

УДК 617.53-002.36-06:616.211/.232]-08
DOI <https://doi.org/10.31379/2411.2616.18.2.2>

АНЕСТЕЗІОЛОГІЧНИЙ МЕНЕДЖМЕНТ ПОРУШЕНИХ ДИХАЛЬНИХ ШЛЯХІВ ВНАСЛІДОК СИНДРОМУ ЛЕМ'ЄРА

Д. Леві, К. Флавер, Т. Хайнд, Т. Алі, С. Винол, А. Варвинський

Синдром Лем'єра – це небезпечна для життя інфекція м'яких тканин шиї. Ми описуємо анестезіологічне забезпечення у пацієнтів з порушенням дихальних шляхів через сильний набряк м'яких тканин, пов'язаний із синдромом Лем'єра. У цьому випадку передопераційна комп'ютерна томографія та ендоскопія носа відобразить анатомію. Бригаду отоларингологів підготували до невідкладної допомоги, щодо дихальних шляхів. Зволожений назальний кисень із високим потоком повітря забезпечує максимальну оксигенацію під час фібро-оптичної інтубації та час, доступний для термінової трахеостомії, якщо потрібно.

Ключові слова: анестезія, фібро-оптична інтубація, синдром Лем'єра.

UDC 617.53-002.36-06:616.211/.232]-08
DOI <https://doi.org/10.31379/2411.2616.18.2.2>

THE ANAESTHETIC MANAGEMENT OF A COMPROMISED AIRWAY SECONDARY TO LEMIERRE'S SYNDROME

D. Levy, K. Flower, T. Hinde, T. Ali, C. Vinall, A. Varvinskiy

Lemiere's syndrome is a life-threatening soft tissue infection of the neck. We describe the anaesthetic management of a patient presenting with a compromised airway due to severe soft tissue swelling associated with Lemierre's syndrome. In this case, preoperative computed tomography and nasal endoscopy delineated the anatomy. The otolaryngology team were prepared for an airway emergency. High flow humidified nasal oxygen maximised oxygenation during awake fiberoptic intubation and the time available for rescue tracheostomy if required.

Key words: anaesthesia, awake fiberoptic intubation, Lemierre's syndrome.

Abbreviations:

HFNO: High Flow Humidified Nasal Oxygen

AFOI: Awake fiberoptic intubation

Introduction. Lemiere's syndrome describes a severe soft tissue infection of the head and neck leading to internal jugular vein thrombosis and septic emboli, most com-

monly to the lungs. It typically occurs following infections of the tonsils or pharynx, although tooth extraction is a rare but recognised cause [1, 2]. The most common causative organism is the gram-negative anaerobic bacterium *Fusobacterium necrophorum* [3]. Prior to the development of antibiotics, mortality was said to be as high as 90% but following their introduction, the incidence of Lemierre's syndrome has fallen so low that it has been referred to as the "forgotten disease" [3, 4]. A more recent increase in the number of documented cases may indicate a rise in incidence, possibly due to antibiotic resistance and changes in prescription patterns [2]. The majority of those affected are previously healthy children and young adults [4]. It most commonly presents with sore throat, fever, dysphagia, trismus, neck mass and pain, potentially making airway management extremely challenging [2, 3]. Other symptoms may include pleuritic chest pain, dyspnoea and haemoptysis [4]. Management should focus on surgical drainage of abscess in combination with targeted antibiotic therapy, while the role of anticoagulation for venous thrombosis remains controversial [2].

A variety of methods have been described in the literature for airway management in the presence of soft tissue infections of the neck, including intravenous and gas inductions, direct laryngoscopy, blind nasal intubation, asleep and awake fiberoptic intubation and awake tracheostomy [5]. Case reports exist describing the use of cervical plexus blocks to allow incision and drainage, avoiding instrumentation of the airway [6]. We present the case of an immunosuppressed patient requiring emergency incision and drainage of a large neck abscess, and the steps we took to minimise the risk associated with endotracheal intubation.

Case Presentation. A 67 year-old lady presented to Torbay Hospital, a district general hospital, three days following the extraction of her lower right wisdom tooth with swelling and pain of her right jaw and neck, swelling of her tongue and difficulty swallowing. Medical history included rheumatoid arthritis managed with hydroxychloroquine and methotrexate. Examination revealed significant submandibular swelling extending to the submental region, and erythema extending to her sternal notch. Mouth opening was reduced to 15mm, Mallampati score was 3 and neck extension was significantly limited due to the sizeable right sided neck swelling and pain and her underlying rheumatoid arthritis. In spite of these findings, she was physiologically more stable than expected. Computed tomography of the neck demonstrated a right submandibular, buccal and sublingual collection extending to the right parapharyngeal, carotid, retropharyngeal and prevertebral spaces. This had resulted in displacement of the oropharynx to the left and narrowing of the airway superiorly. Infection had extended so far as to cause apical lung abscesses and had led to a right internal jugular thrombosis.

Appropriate antibiotics and a course of dexamethasone were commenced. A fiberoptic nasendoscopy performed by the otolaryngology team demonstrated right parapharyngeal swelling and an oedematous right arytenoid, but importantly showed mobile vocal cords and suggested fiberoptic intubation would be possible. The tertiary centre cardiothoracics team reviewed the images and felt a thoracoscopic washout was not necessary.

Following administration of glycopyrrolate as an anti-sialagogue, High Flow Humidified Nasal Oxygen (HFNO: Optiflow™ Fisher and Paykel) was commenced and with remifentanyl sedation. The nasal and oral mucosa were anaesthetised with direct sprays of 4% lidocaine and the airway was anaesthetised with 1ml aliquots of 4% lidocaine plus 9ml of air ejected from the working channel of fiberoptic scope. Awake fiberoptic intubation (AFOI) demonstrated significant distortion of the anatomy but

was well tolerated with oxygen saturations maintained throughout and a cuffed nasal endotracheal tube was passed on the first attempt without issue. Following induction of general anaesthesia copious pus was irrigated from the sublingual, submandibular and parapharyngeal spaces.

The patient was admitted to intensive care and electively extubated the next day after demonstration of a cuff leak and further fiberoptic examination by the otolaryngology team. Following successful extubation, the patient was transferred to the ward to continue intravenous antibiotics and observation. The patient was discharged six days later with oral antibiotics and cessation of immunosuppression medication until follow up in six weeks by the respiratory team regarding the apical lung abscesses.

Discussion. Soft tissue infections of the neck present a multitude of problems for the anaesthetist. This patient group may be haemodynamically compromised as a result of sepsis. Airway swelling can make visualisation of the anatomy extremely difficult. Induction prior to securing of the airway risks airway collapse and an inability to ventilate. The potential for infection to progress rapidly can preclude deferring for more experienced hands. Swelling can be so significant as to occlude PVC tracheal tubes [7]. Traumatic intubation may release pus, obscure the view and potentially lead to contamination of the bronchial tree [8]. Anterior spread of infection can make surgical tracheostomy difficult due to the surrounding induration and is a relative contraindication due to the risk of mediastinal spread [8, 9].

In this case we anticipated that that face-mask ventilation and direct laryngoscopy might be difficult or impossible. Features of particular concern in this patient were trismus, dysphagia, reduced neck extension and abscess of the neck with radiological evidence of compression and distortion of the airway. It is possible that induction of general anaesthesia prior to securing the airway could have caused complete airway obstruction with the relaxation of the pharyngeal muscles. We were also concerned that efforts at direct laryngoscopy may lead to traumatic rupture of the abscess causing contamination of the airway. It was our assessment that AFOI was the safest option available for airway management to allow surgical drainage of the sizeable abscess.

Appropriate preparation included the presence of an experienced anaesthesiologist and assistant and consideration of alternative airway plans, thus ensuring that the otolaryngology team were aware and prepared for an airway emergency. A multidis-

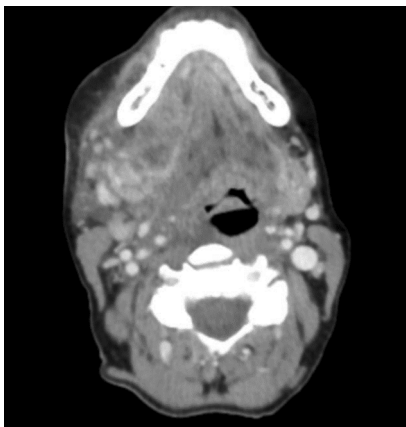


Fig. 1. Axial slice computed tomography demonstrating a large collection displacing the oropharynx to the left

ciplinary approach established that the case was conducted in the appropriate facility. Preoperative nasendoscopy allowed anatomical assessment to discern whether AFOI was likely to succeed. HFNO has previously been demonstrated to be well tolerated in spontaneously breathing patients undergoing AFOI and may potentially prevent desaturation arising as a result of apnoea or hypoventilation [10]. In this case it did not hinder AFOI, maximising oxygenation and the time available for rescue tracheostomy if it were to be required. AFOI proved to be a good option as it was well tolerated allowed good visualisation of the anatomy, and minimised trauma.

We concluded that long-term immunosuppressants may have masked the significant inflammatory response expected in this case, highlighting how initial appearances may be deceptive. It is possible that had we not intervened in a timely manner, the airway compromise may have progressed further making endotracheal intubation unlikely to succeed. Challenges included the co-ordination of diagnosis and planning between five clinical teams over two sites. This meant that time critical source control occurred late in the evening with potentially fewer resources available.

Odontogenic infection is an uncommon precipitant of Lemierre's syndrome, a rare disease with an apparently increasing incidence [1]. With the potential to present as an airway emergency requiring urgent drainage, it is a disease that anaesthesiologist and critical care physicians should be familiar with.

Conflict of Interest. None declared.

Patient Consent Form. Informed patient consent was obtained for this case report. Patient consent related case report take the permission from concerned patient.

ЛІТЕРАТУРА

1. Lemierre's syndrome: a serious complication of a routine dental procedure / B. Ghaly, A. Bertram, A. Naim // *Australian Dental J.* – 2013. – Iss. 58. – P. 246–249.
2. Lemierre's syndrome: A systematic review / P.D. Karkos [et al.] // *Laryngoscope.* – 2009. – Iss. 119. – P. 1552–59.
3. Lemierre's syndrome / W. Eibert, N. Singla // *Int J Emerg Med.* – 2013. – Iss. 6. – P. 40.
4. Lemierre's syndrome from odontogenic infection: Review of the literature and case description / D. Noy [et al.] // *Ann Maxillofac Surg.* – 2015. – Iss. 5. – P. 219–25.
5. Ludwig's angina. The anaesthetic management of nine cases / T.E. Loughnan, D.E. Allen // *Anaesthesia.* – 1985. – Iss. 40. – P. 295–7.
6. Decompression of Ludwig's angina under cervical block / M. Manish, S. Mehrotra // *Anesthesiology.* – 2002. – Iss. 97. – P. 1625–6.
7. Ludwig's angina and tracheal tube obstruction / R.A. Chung, J.B. Liban // *Anaesthesia.* – 1991. – Iss. 46. – P. 228–239.
8. Airway Management in Ludwig's Angina / S.P.W. Neff, A.F. Merry // *Anaesth Intensive Care.* – 1999. – Iss. 27. – P. 659–661.
9. Anaesthetic management of Ludwig's angina with comorbidities / M.P. Sujatha [et al.] // *Indian J Anaesth.* – 2015. – Iss. 59. – P. 679–681.
10. Optimizing oxygenation and intubation conditions during awake fibre-optic intubation using a high-flow nasal oxygen-delivery system / S. Badiger [et al.] // *Br J Anaesth.* – 2015. – Iss. 115. – P. 629–632.

REFERENCES

1. Ghaly, B., Bertram, A., Naim, A. Lemierre's syndrome: a serious complication of a routine dental procedure. *Australian Dental J.*, 2013, iss. 58, p. 246–249.

2. Karkos, P.D. et al. Lemierre's syndrome: A systematic review. *Laryngoscope*, 2009, iss. 119, p. 1552–59.
3. Eilbert, W., Singla, N. Lemierre's syndrome. *Int J Emerg Med*, 2013, iss. 6, p. 40.
4. Noy, D. et al. Lemierre's syndrome from odontogenic infection: Review of the literature and case description. *Ann Maxillofac Surg*, 2015, iss. 5, p. 219–25.
5. Loughnan, T.E., Allen, D.E. Ludwig's angina. The anaesthetic management of nine cases. *Anaesthesia*, 1985, iss. 40, p. 295–7.
6. Manish, M., Mehrotra, S. Decompression of Ludwig's angina under cervical block. *Anesthesiology*, 2002, iss. 97, p. 1625–6.
7. Chung, R.A., Liban, J.B. Ludwig's angina and tracheal tube obstruction. *Anaesthesia*, 1991, iss. 46, p. 228–239.
8. Neff, S.P.W., Merry, A.F. Airway Management in Ludwig's Angina. *Anaesth Intensive Care*, 1999, iss. 27, p. 659–661.
9. Sujatha, M.P. et al. Anaesthetic management of Ludwig's angina with comorbidities. *Indian J Anaesth*, 2015, iss. 59, p. 679–681.
10. Badiger, S. et al. Optimizing oxygenation and intubation conditions during awake fibre-optic intubation using a high-flow nasal oxygen-delivery system. *Br J Anaesth*, 2015, iss. 115, p. 629–632.

Submitted 01.12.21

Reviewer prof. Yu.Iu. Kobeliatskyi, date of review 06.12.21